



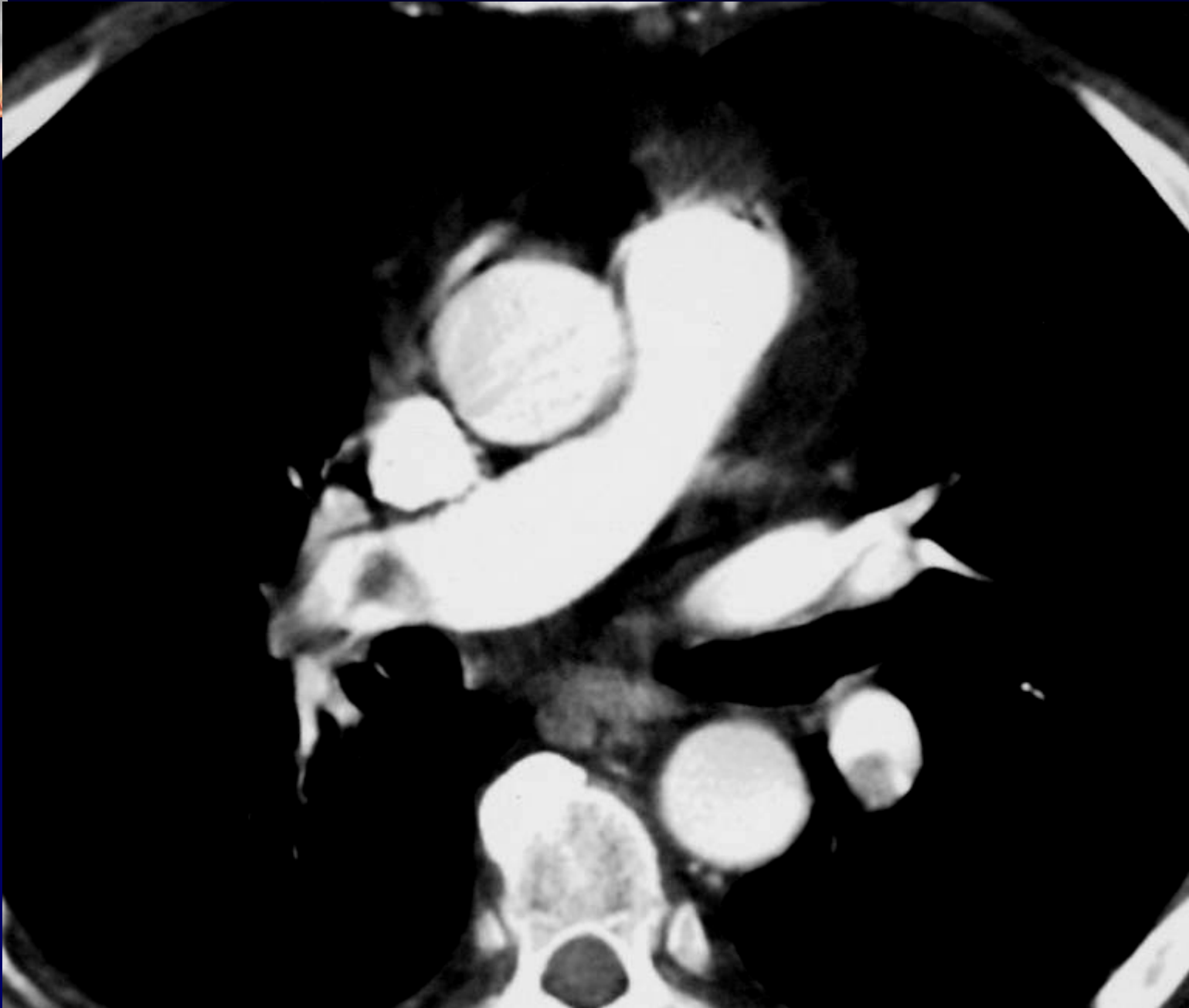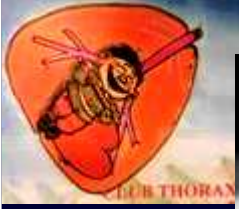Dossier 3

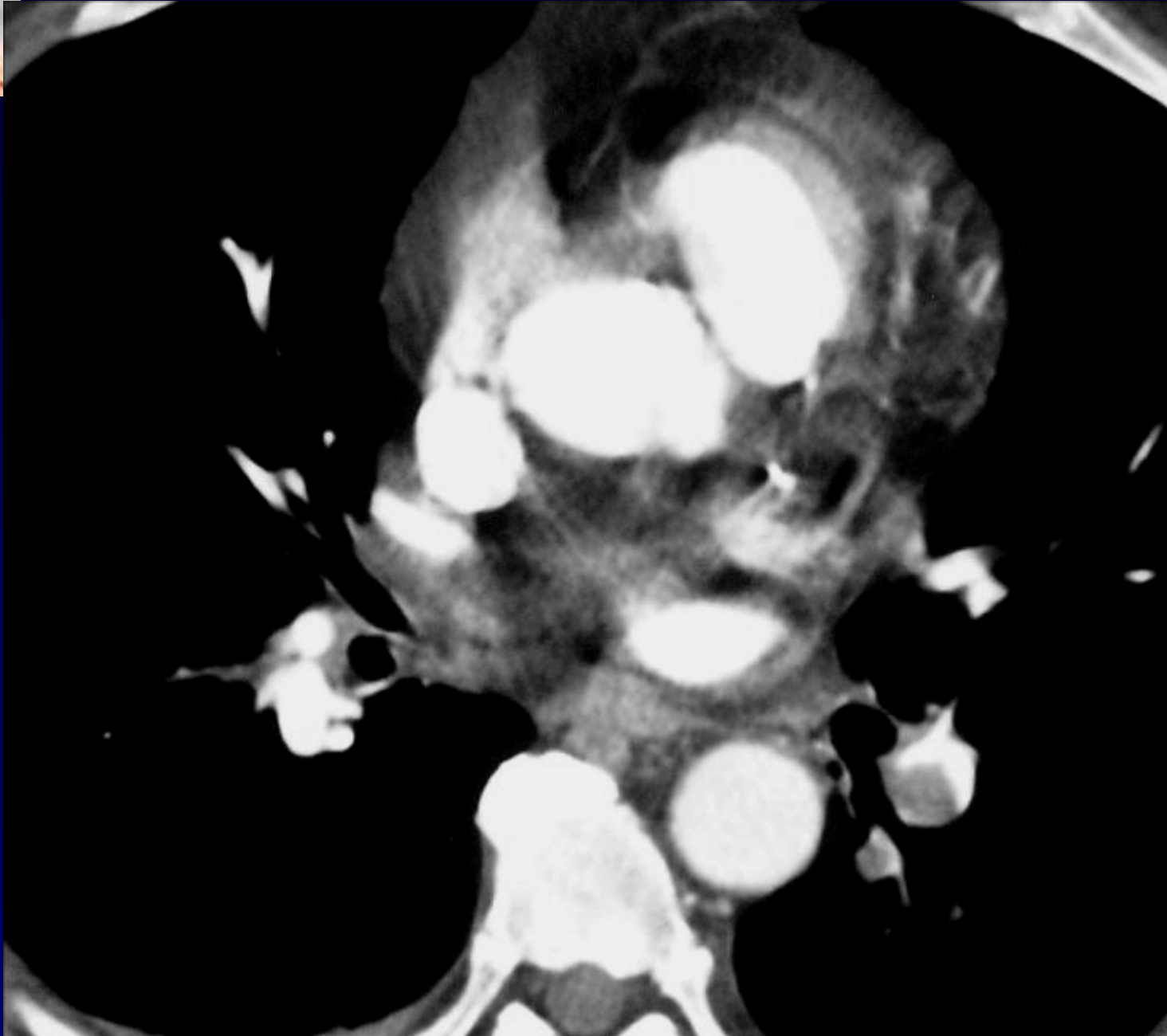
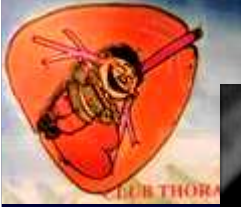P. LACOMBE

M. EL HAJJAM

Homme de 66 ans

Dyspnée







Diagnostic ?

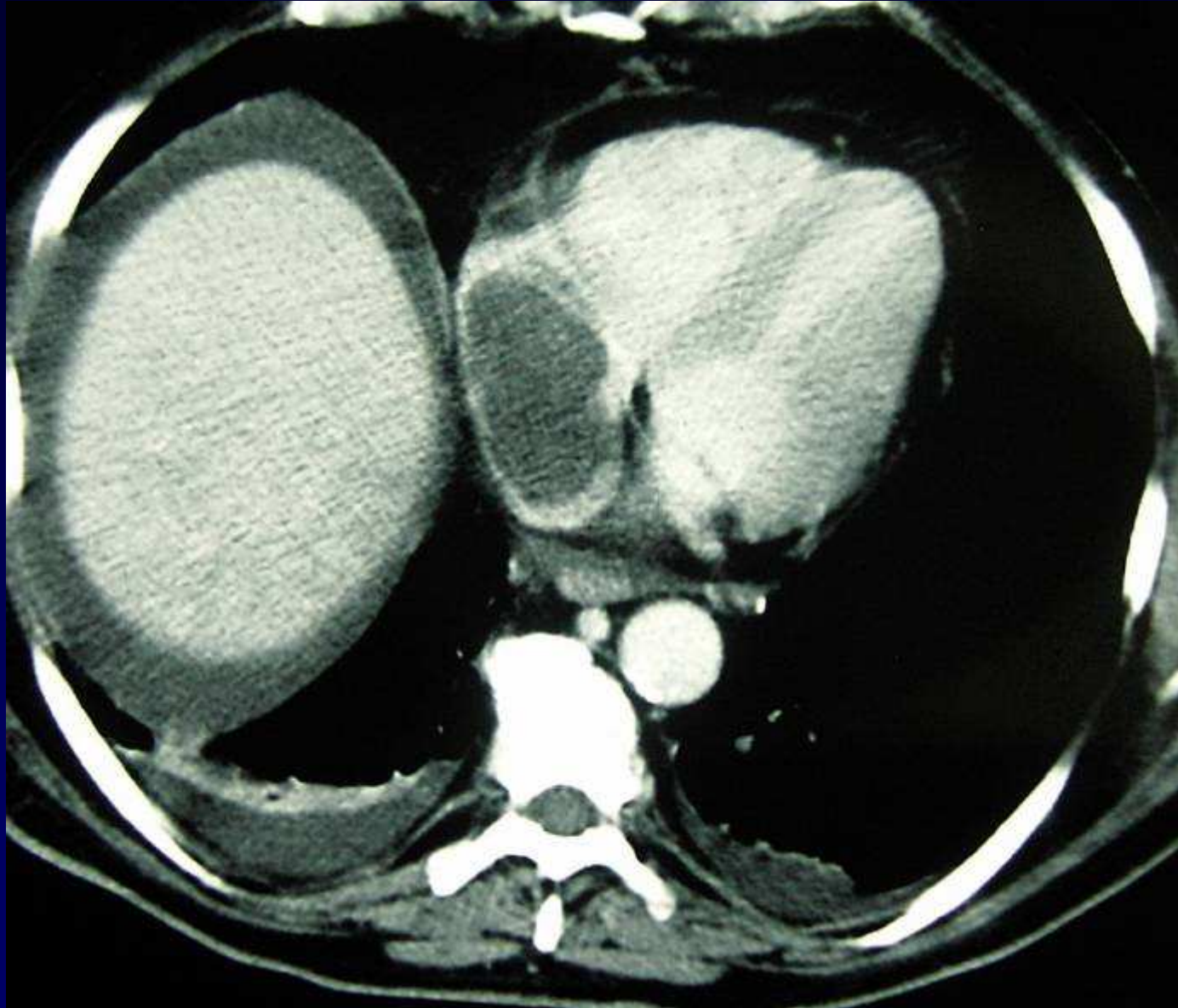


Diagnostic

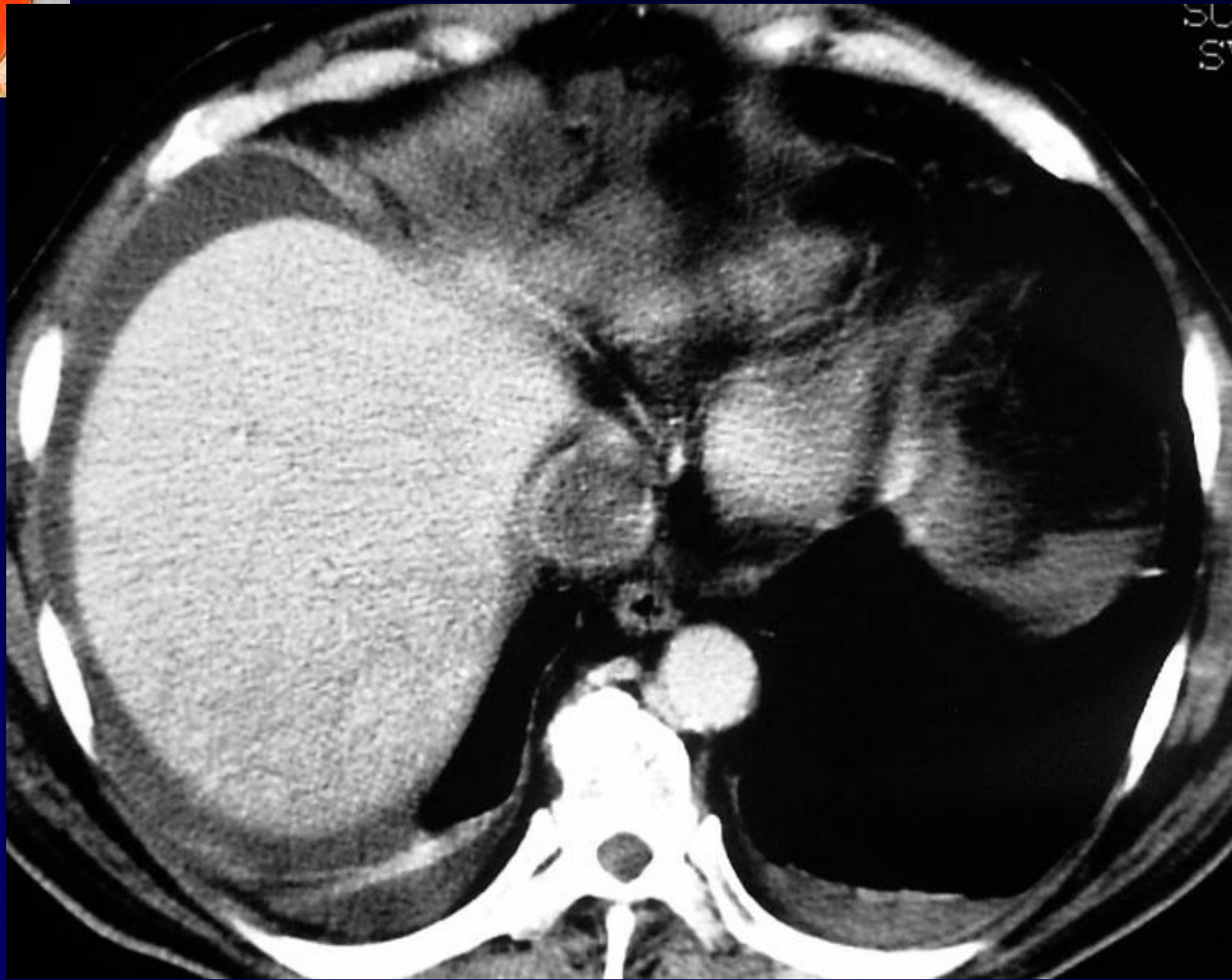
Embolie pulmonaire aigue.

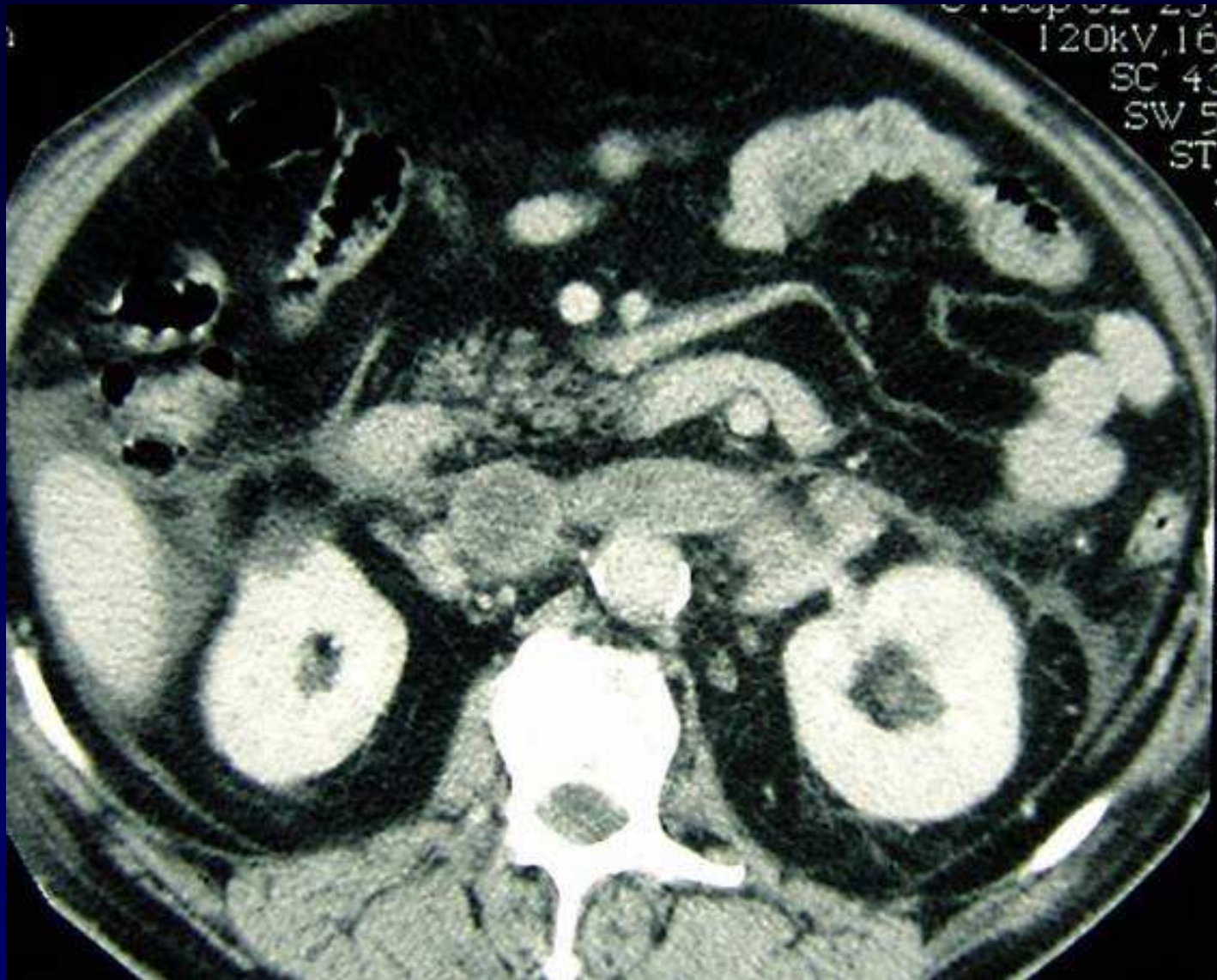
Anticoagulation

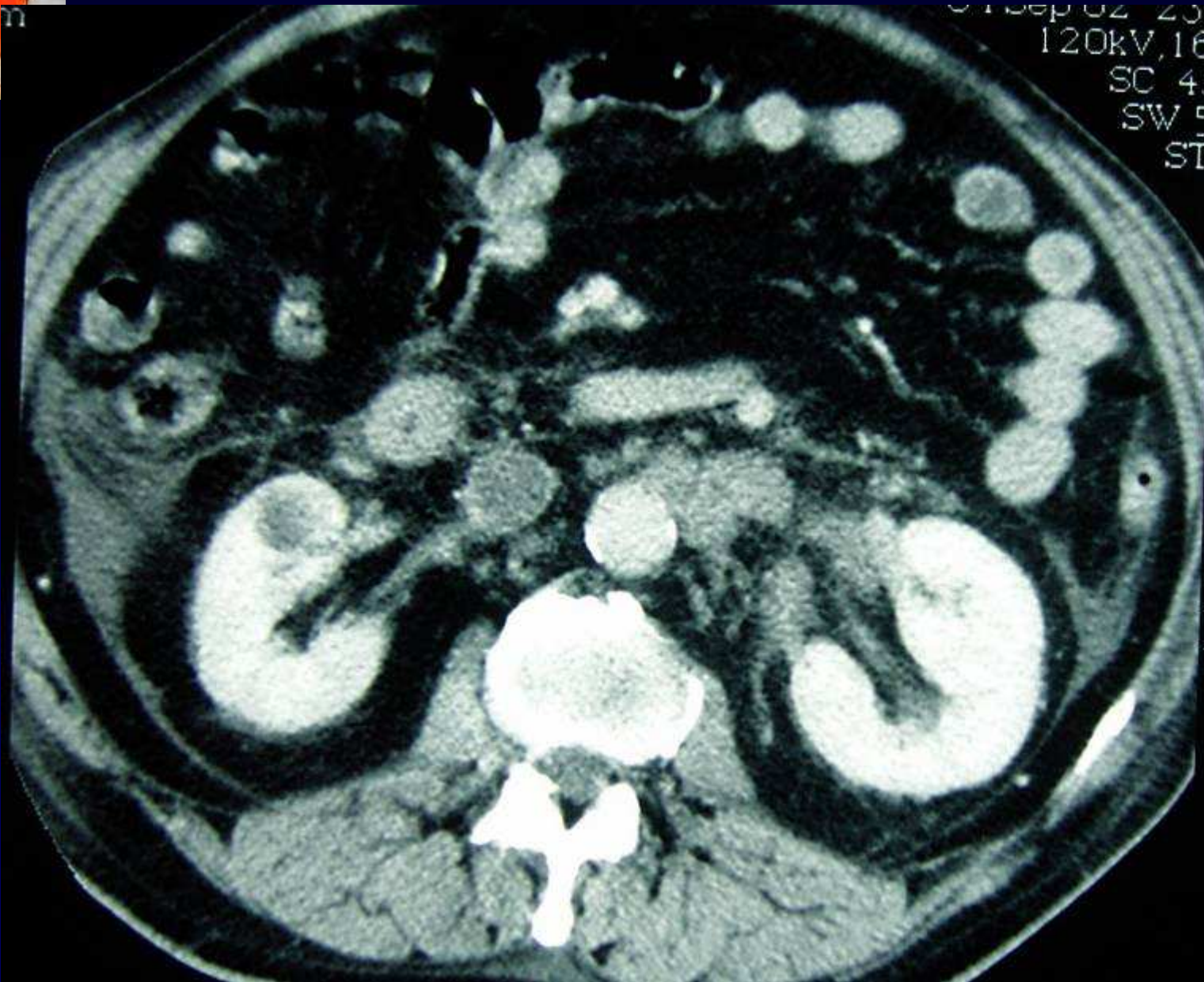
Mais.....



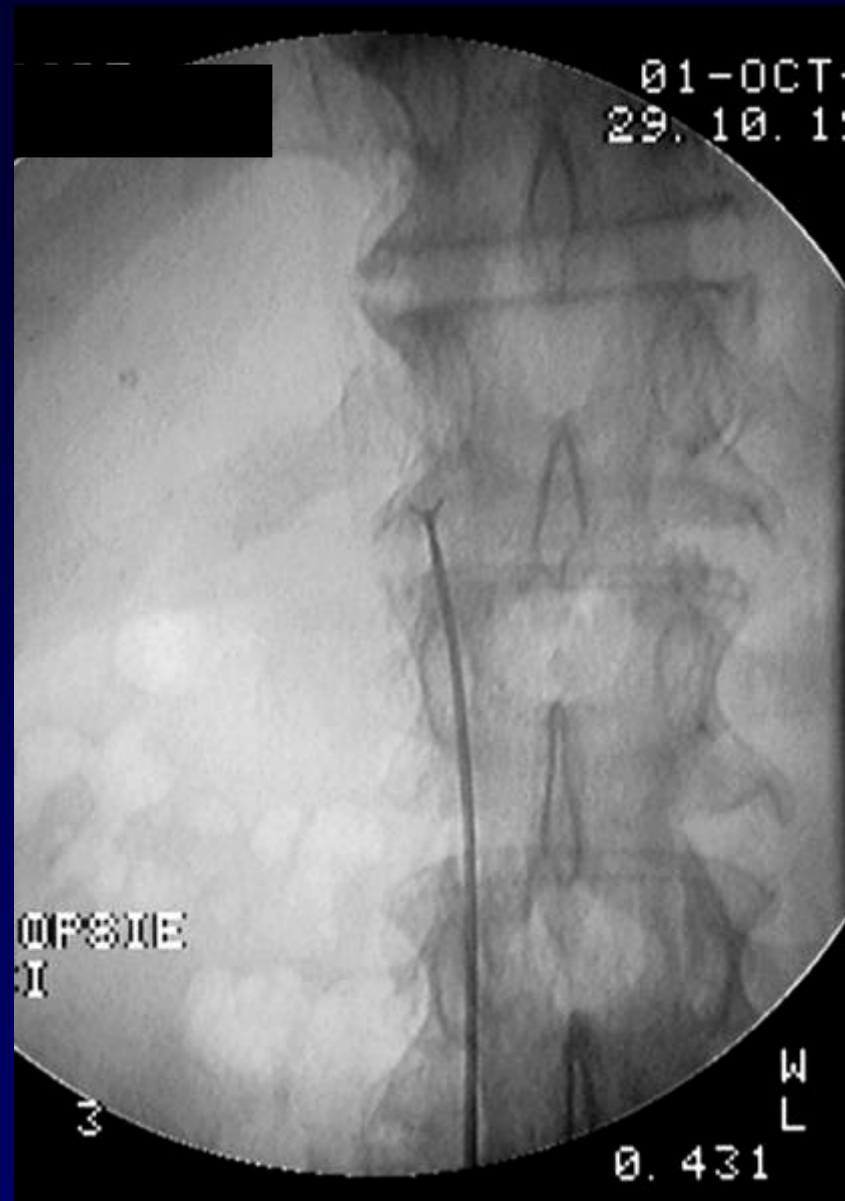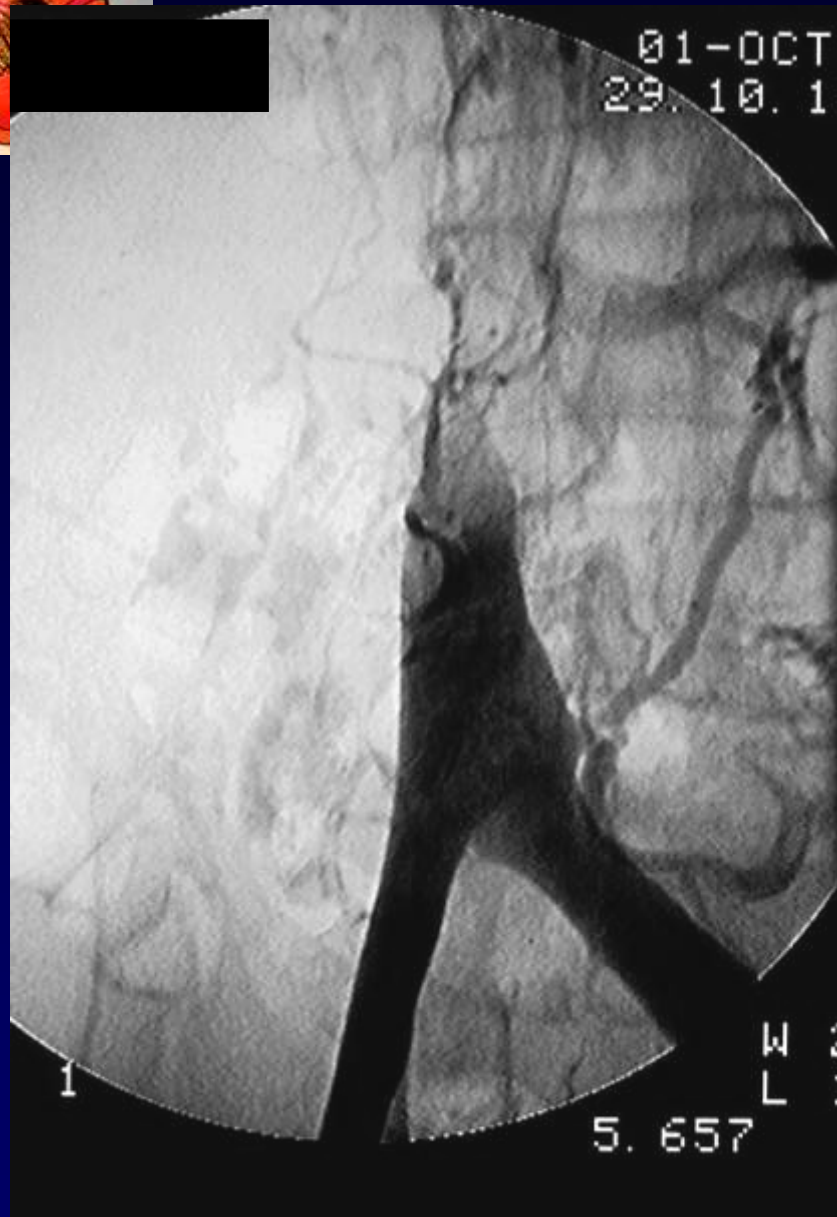
Récidive et aggravation au bout de 2 mois



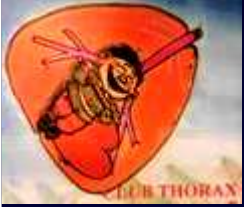



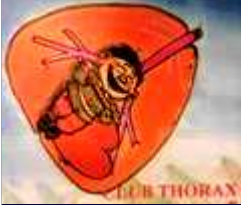01 Sep 02 20
120kV, 16
SC 40
SW 5
ST



Biopsies intra-cave inférieure



Diagnostic ?



Diagnostic

- 1: [Int J Cardiol.](#) 2006 Sep 20;112(2):247-8. Epub 2005 Oct 18.

Recurrent pulmonary embolism with non-mobile thrombus in a patient with leiomyosarcoma of the left renal vein.

[Mansencal N](#), [El Hajjam M](#), [Vieillard-Baron A](#), [Pelage JP](#), [Lacombe P](#), [Dubourg O](#).

We describe the case of a man who suffered recurrent pulmonary embolisms despite well-conducted oral anticoagulant therapy. Echocardiography and helical computed tomography revealed a non-mobile right atrial mass related to a leiomyosarcoma of the left renal vein. The prognosis of such a disease is bad and the patient died at 1-year follow-up. Recurrent pulmonary embolism with well-conducted oral anticoagulant therapy requires further appropriate investigations, because of high suspicion of neoplastic process.

PMID: 16239040 [PubMed - indexed for MEDLINE]

Codage : Poumon – Cardiovasculaire – Tumoral malin - Autres